

## Case Report

# Unusual Presentation of Brain Tumor in a Child: A Case Report

**Mahmoud Alhandi Omar Helal<sup>1,2,3,\*</sup>, Mohammed Al-Amri<sup>1</sup>, Mahmoud Alrifaii<sup>1</sup>,  
Shaikha Al-Thani<sup>4</sup>, Bashir Youssef<sup>1</sup>, Lujain Loay<sup>1</sup>, Abdulrahman Siddig<sup>5</sup>,  
Hanan Eldesouky Eltomy<sup>1</sup>**

<sup>1</sup>Division of Pediatric Emergency Medicine, Department of Pediatrics, Hamad Medical Corporation, Doha, Qatar

<sup>2</sup>Pediatric Nephrology Department, Faculty of Medicine, Aleppo University, Aleppo, Syria

<sup>3</sup>Department of Pediatrics, Alwakra Hospital, Alwakra, Qatar

<sup>4</sup>Faculty of Medicine, Weill Cornell University, Doha, Qatar

<sup>5</sup>Pediatric Department, Sidra Hospital, Doha, Qatar

## Email address:

Mhelal1@hamad.qa (Mahmoud Alhandi Omar Helal), Malamri@hamad.qa (Mohammed Al-Amri), Malrifaii@hamad.qa (Mahmoud Alrifaii), sha2053@qatar-med.cornell.edu (Shaikha Al-Thani), BYOUSSEF@hamad.qa (Bashir Youssef), LLOYAY@hamad.qa (Lujain Loay), AGamil1@hamad.qa (Abdulrahman Siddig), HELTOMY@hamad.qa (Hanan Eldesouky Eltomy)

\*Corresponding author

## To cite this article:

Mahmoud Alhandi Omar Helal, Mohammed Al-Amri, Mahmoud Alrifaii, Shaikha Al-Thani, Bashir Youssef, Lujain Loay, Abdulrahman Siddig, Hanan Eldesouky Eltomy. Unusual Presentation of Brain Tumor in a Child: A Case Report. *American Journal of Pediatrics*. Vol. 9, No. 2, 2023, pp. 63-67. doi: 10.11648/j.ajp.20230902.12

**Received:** March 20, 2023; **Accepted:** April 17, 2023; **Published:** April 27, 2023

**Abstract:** The most popular type of neurological tumor in childhood is medulloblastoma, which is the most malignant neoplasm of the posterior fossa and cerebellum. Central nervous system neoplasms can cause symptoms and signs due to local invasion, compression of normal structures, and increased intracranial pressure by either a mass effect or obstruction of cerebrospinal fluid flow, resulting in hydrocephalus. Usually, headache is the most common symptom of central nervous system tumors, and the median duration between symptoms beginning and diagnosis of brain tumors in children ranges from 2.5 to 3.5 months. Furthermore, several predisposing factors for brain tumors have been identified such as Epstein-Barr virus infection, exposure to ionizing radiation, and inherited diseases. Recently, the advances in diagnosis and treatment have improved the survival of many children with neurological neoplasms. However, this therapy is associated with long-term complications, and its prognosis remains poor. We present the case of a 4-year-old girl with adequate neuropsychomotor development who presented to the pediatric emergency center with a 14-day history of headache, which was prominent in the morning, neck, back, and bilateral leg pain two days prior to presentation. Brain and Spine Magnetic resonance imaging revealed a cerebellar mass lesion in the posterior fossa. The patient underwent surgery, followed by histopathological and immunohistochemical staining. This case is considered rare and distinctive because the symptoms included only headache for two weeks, no impaired vision, no vomiting, no mental disorders, no abnormal gait, and no ataxia or body imbalance. We report this case to focus on the features of the manifestation and hence increase the chances of timely diagnosis in the future. Consequently, the probability of central nervous system tumors should always be considered in children with headache, and they must be under regular follow-up for early diagnosis and treatment.

**Keywords:** Childhood Tumor, Brain Tumor, Medulloblastoma, Malignancy in Children, Pediatric Cancer

## 1. Introduction

Neurological neoplasms are the most common solid tumors

and are a major cause of malignant-related death in children. [1-3] Tumors of the central nervous system (CNS) account for 20% of childhood malignancies and are second to leukemia in

recurrence. [4] The annual incidence of brain tumors related to age in children is 5.65 cases per 100,000 population. Nevertheless, the mortality is 0.72 case per 100,000. [3] Recent advances in diagnosis and treatment have improved the survival and fineness of life of many children with CNS neoplasms. However, this therapy is associated with long-term complications, and the prognosis remains poor. [2-5]

Medulloblastoma is the most popular CNS tumor in children. [6] Which generally grows in the cerebellum; therefore, patients present with signs of increased ICP or cerebellar dysfunction. More than 60% of children with embryonal neoplasms are medulloblastomas, and 70% occur under the age of 10 years, affecting more males than females. [3, 7, 8] More than 30% of cases are under the age of 3 years. [9]

CNS neoplasms can cause symptoms and signs of local invasion, compression of adjacent structures, and increased ICP by either a mass effect, which compresses normal CNS structures, or by causing obstruction of cerebrospinal fluid flow, resulting in hydrocephalus.

Headache is the most common symptom of CNS tumors, occurring in approximately one-third of affected children. Infants and young children may be unable to articulate the source of their discomfort and are more likely to present with irritability.

Headaches associated with CNS tumors are generally thought to be caused by increased ICP. These headaches are classically described as early morning headaches, which are often relieved

by vomiting. However, many children do not present with these symptoms. This was illustrated in a case series of 200 children with CNS tumors that recorded the pattern of headaches in 71 of 112 patients who presented with headaches [10]. Headaches were nocturnal or occurred early in the morning in 43 patients, during the daytime or early evening in 15, and were continuous in the remaining 13 patients.

Nausea and vomiting are common symptoms of CNS tumors in children of any age [11].

The diagnosis of a CNS tumor is based on the identification of the lesion by neuroimaging, either by magnetic resonance imaging (MRI) or computed tomography (CT). Histological examination is required to diagnose specific tumor types.

Childhood brain neoplasms have various manifestations depending on the tumor place, age, and biology. Therefore, a prolonged symptom duration is present, which is related to increased morbidity, and psychosocial distress for children, parents, and healthcare providers [12, 13].

In the United Kingdom, a systematic review reported that the median symptom durations between symptom beginning and diagnosis of brain tumors in children ranges from 2.5 to 3.5 months [13].

The decision to perform imaging studies is based on clinical suspicion that the signs and symptoms are due to a brain neoplasm. Table 1 reports the indications for neuroimaging to minimize delays in diagnosis, as recommended by a 2010 evidence-based guideline developed in the United Kingdom [13].

**Table 1.** Indications for neuroimaging in children with a suspected brain tumor.

<i>Persistent headache</i> (defined as a continuous or recurrent headache lasting for >4 weeks) with any of the following features:	1) Wakes a child from sleep. 2) Occurs upon waking. 3) Occurs in a child <4 years of age. 4) Associated with disorientation or confusion.
<i>Persistent vomiting upon waking</i>	
<i>Visual findings</i>	1) Papilledema. 2) Optic atrophy. 3) New-onset nystagmus. 4) Reduced acuity not due to refractive error. 5) Visual field reduction. 6) Proptosis. 7) New-onset paralytic squint.
<i>Motor findings</i>	1) Regression in motor skills. 2) Focal motor weakness. 3) Abnormal gait and/or coordination. 4) Bell's palsy with no improvement over four weeks. 5) Swallowing difficulties without an identifiable local cause.

Since many signs and symptoms of CNS neoplasms in childhood are nonspecific and heterogeneous, CNS tumors can be misdiagnosed as common childhood conditions such for example (viral gastroenteritis, tension, and migraine headaches). Less common neurological conditions that may mimic the presentation of a brain tumor include brain abscesses, intracranial hemorrhage, non-neoplastic hydrocephalus, arteriovenous malformations, aneurysms, or indolent viral infections.

Children with CNS tumors generally present with more than one tumor-associated symptom or sign, allowing CNS tumors to be clinically distinguished from other conditions.

For example, as discussed above, children with headaches associated with CNS tumors typically have other CNS manifestations including vomiting, vision impairment, unsteady gait, changes in behavior or school performance, sleep disturbances, and growth impairment [10]. However, neuroimaging is needed to definitively differentiate CNS tumors from other diagnoses, and should be performed in any child suspected of having a CNS lesion.

Poor prognosis of medulloblastoma is associated with presentation at diagnosis, such as; dissemination, size, children less than 3 years of age, and residual size more than 1.5-2 cm on imaging after surgery. [6]

Predisposing factors for brain neoplasms include radiation therapy, exposure to ionizing radiation, and atomic bomb survivors, which cause meningiomas, gliomas, and nerve sheath neoplasms [14].

Cellular telephones are a source of radiofrequency fields that have received coverage in popular media as potential risk factors for brain tumors, presumably due to the exposure of the head of the user to radiofrequency energy. Other causes of exposure to radiation include microwave, radar equipment, and provisional exposures (sealers, plastic welders, amateur radio operators, and medical and telecommunications workers).

Hardly, exposure to radiation can be quantified even in advanced laboratories. [15].

Numerous epidemiological studies have examined the possible relationship between cellular telephone use and the development of brain tumors [16, 17]. A meta-analysis of 22 blinded case-control studies found that there was a slight risk related to the using of cell phones, which showed that the relationship appeared to be associated with an induction duration of 10 years or more [16]. Furthermore, radiofrequency electromagnetic fields were classified as a carcinogenic to humans by the World Health Organization [18].

In a study of 228,055 Danish patients admitted for head trauma and followed up for eight years, there was a significant increase in the risk of hemangioma and hemangioblastoma [19].

Childhood brain tumors may be more common in first-born children (higher risk of birth trauma) and in children with a confirmed history of delivery trauma (prolonged labor, forceps delivery, and cesarean section) [20].

There is increasing consensus on the inverse association between allergies (such as asthma, eczema, and hay fever) and glioma risk based on consistent findings across different populations and study designs [21, 22].

A large study, found that children who reported a history of infectious diseases, such as upper respiratory infections, compared with those who did not, had a 30 per cent reduction in risk (relative risk [RR] = 0.72, 95% CI 0.61-0.85) [23].

Other infectious predisposing factors include neonatal viral infections, polyomavirus, infection with *Toxoplasma gondii*, and simian virus 40 (SV40).

Approximately 1–5 percent of brain neoplasm due to genetic syndromes that increase the risk of growing tumors of the nervous system [22, 24, 25]. Some of these tumors are associated with neurofibromatosis and several other inherited syndromes.

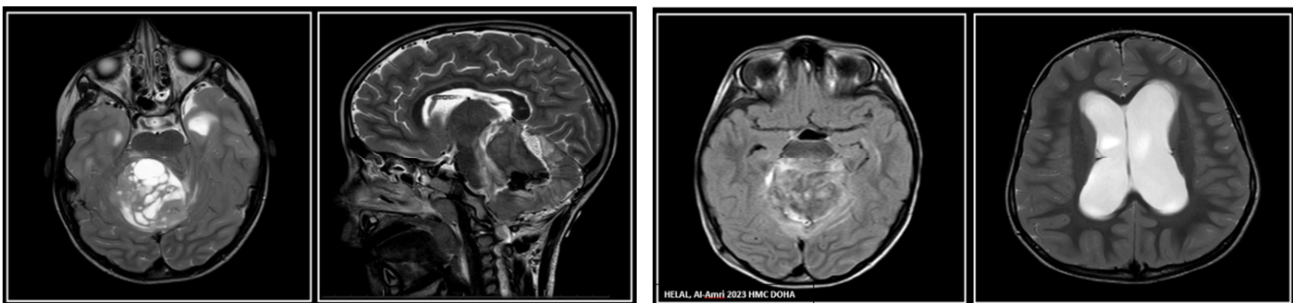
## 2. Case Report

A 4-year-old girl with adequate neuropsychomotor development presented to the pediatric emergency center on November 18, 2022, with a 14-day history of headache, which was prominent in the morning, neck, back, and bilateral leg pain two days prior to presentation. The patient had a history of upper respiratory tract infection 14 days prior to presentation and no history of trauma, loss of consciousness, visual disturbance, nausea, vomiting, poor appetite, nasal congestion, tachypnea, diarrhea, or skin rash. The patient's temperature was 37.4°C, heart rate was 113 beats/min, blood pressure was 101/60 mmHg, respiratory rate was 28 breaths/min, and oxygen saturation was 100% on room air.

On physical examination, the patient was lying comfortably and was not in any distress. Examination of her neck, there was neck stiffness, her right tonsil was enlarged, and upon examination of her jaw, there was one large lymph node below her right jaw. No other meningeal signs were observed, and her cardiac, abdominal, and pulmonary examinations were insignificant. The patient's weight and length were according to her age. Laboratory investigations were as follows: COVID-19 PCR was negative; complete blood count was normal at  $13.7 \times 10^3$  white blood cells (WBCs)/ $\mu\text{L}$  (normal,  $5\text{--}15 \times 10^3$  WBC/ $\mu\text{L}$ ) with 82% neutrophils; liver and kidney functions were normal; electrolytes were normal; and C-reactive protein level was 1 mg/dl (normal 0–5 mg/L). The respiratory virus PCR panel was negative, urine and blood cultures were negative, and soft tissue radiography of the neck was normal. Brain and Spine Magnetic resonance imaging (MRI) was performed, which revealed a posterior fossa cerebellar mass lesion with secondary supratentorial obstructive hydrocephalus and cerebellar tonsillar herniation, indicative of medulloblastoma. Small adjacent right superior cerebellar leptomeningeal nodular lesions were noted, consistent with localized leptomeningeal extension. No other metastatic deposits were noted (Figure 1).

The patient underwent surgery, followed by histopathological analysis, which suggested a Frozen Section that showed a lesion of very high cellularity, with primitive-looking cells mostly without cytoplasm. Necrosis is present. The frozen sections showed a similar appearance to that of the tumor tissue. Cytomorphology was highly suggestive of medulloblastoma.

Surgical Histopathology report:



**Figure 1.** MRI of brain showed a posterior fossa mixed cystic-solid mass lesion centred on the right cerebellar hemisphere medially extending into middle cerebral peduncle and superior along the vermis where it occupies the quadrigeminal and right ambient cisterns. It measures 5.1 x 5.0 x 4.6 cm.

A highly cellular lesion essentially consists of a syncytial arrangement of densely packed undifferentiated cells with little or no cytoplasm, and hyperchromatic, moderately enlarged, and moderately pleomorphic nuclei. A nodular appearance was observed in some areas, as shown by reticulin staining. Mitotic figures and apoptotic materials were also abundant. Homer Wright rosettes were also present. Ki67 immunohistochemistry shows a high MIB index. Immunohistochemically, the tumor cells were positive for synaptophysin and CD56. The infiltrative nature of the tumor was demonstrated by GFAP immunohistochemistry. The tumor cells showed cytoplasmic  $\beta$ -catenin positivity. Histological findings included medulloblastoma, (WHO grade 4), and classical histology.

### 3. Discussion

However, medulloblastoma is the most common malignant brain cancer in children, accounting for 40% of all pediatric tumors of the posterior fossa. Metastases occur in 20–30% of all medulloblastoma tumors at diagnosis.

A 4-year-old girl was diagnosed with medulloblastoma, confirmed by histopathology and immunohistochemical staining. Causing headache, without other symptoms, for more than two weeks.

This case is considered rare and distinctive because the symptoms included only headache for two weeks, no impaired vision, no vomiting, no mental disorders, no abnormal gait, and no ataxia or body imbalance.

We report this case to focus on the features of the manifestation and hence increase the chances of timely diagnosis in the future. The complexity of clinical and laboratory data makes it possible to suspect oncological diagnosis.

### 4. Conclusion

In summary, the probability of CNS tumors should always be considered in children with headaches. Therefore, these patients must be regularly followed-up for early diagnosis and management.

### Conflicts of Interest

No conflicts of interest for any authors.

### Ethics Approval and Consent to Participate

This case report was approved by the Institutional Review Board (IRB) of the Medical Research Center at Hamad Medical Corporation on 05 February 2023, approval: ID (MRC-04-23-062).

### Consent for Publication

Written informed consent was obtained from the patients'

parents for publication of case details.

### Author Contributions

MAOH, MA, MR, SA, LL, AS, and HE designed this study. Collected data.

MAOH, MA, BY. Analyzed the data. MAOH, SA, and BY. Wrote the manuscript. All authors have reviewed and agreed to the published version of the manuscript.

### Abbreviations

CNS, central nervous system; CT, computed tomography; COVID-19, coronal virus disease 2019, ICP, increased intracranial pressure.

### Acknowledgements

We acknowledge SH. Muneera Al-Thani, Mohammad Alfateh Helal, and the Medical Research Centre at the Hamad Medical Corporation for their support.

### References

- [1] Li BK, Al-Karmi S, Huang A, Bouffet E. Pediatric embryonal brain tumors in the molecular era. *Expert Rev Mol Diagn* 2020; 20: 293-303.
- [2] Pollack IF, Agnihotri S, Broniscer A. Childhood brain tumors: current management, biological insights, and future directions. *J Neurosurg Pediatr* 2019; 23: 261-73.
- [3] Ostrom QT, Gittleman H, Truitt G, Boscia A, Kruchko C, Barnholtz-Sloan JS. CBTRUS statistical report: primary brain and other central nervous system tumors diagnosed in the United States in 2011–2015. *Neuro Oncol* 2018; 20: Suppl 4: iv1-iv86.
- [4] Patel S, Bhatnagar A, Wear C, et al. Are pediatric brain tumors on the rise in the USA? Significant incidence and survival findings from the SEER database analysis. *Childs Nerv Syst* 2014; 30: 147-54.
- [5] Malbari F, Lindsay H. Genetics of common pediatric brain tumors. *Pediatr Neurol* 2020; 104: 3-12.
- [6] Packer RJ, Cogen P, Vezina G, Rorke LB. Medulloblastoma: clinical and biologic aspects. *Neuro Oncol* 1999; 1: 232-50.
- [7] Millard NE, De Braganca KC. Medulloblastoma. *J Child Neurol* 2016; 31: 1341-53.
- [8] Taylor MD, Northcott PA, Korshunov A, et al. Molecular subgroups of medulloblastoma: the current consensus. *Acta Neuropathol* 2012; 123: 465-72.
- [9] Rutkowski S, von Hoff K, Emser A, et al. Survival and prognostic factors of early childhood medulloblastoma: an international meta-analysis. *J Clin Oncol* 2010; 28: 4961-8.
- [10] Wilne SH, Ferris RC, Nathwani A, Kennedy CR. The presenting features of brain tumours: a review of 200 cases. *Arch Dis Child* 2006; 91: 502.

- [11] Wilne S, Collier J, Kennedy C, et al. Presentation of childhood CNS tumours: a systematic review and meta-analysis. *Lancet Oncol* 2007; 8: 685.
- [12] Wilne SH, Dineen RA, Dommett RM, et al. Identifying brain tumours in children and young adults. *BMJ* 2013; 347: f5844.
- [13] Wilne S, Koller K, Collier J, et al. The diagnosis of brain tumours in children: a guideline to assist healthcare professionals in the assessment of children who may have a brain tumour. *Arch Dis Child* 2010; 95: 534.
- [14] Braganza MZ, Kitahara CM, Berrington de González A, et al. Ionizing radiation and the risk of brain and central nervous system tumors: A systematic review. *Neuro Oncol* 2012; 14: 1316.
- [15] Rothman KJ, Chou CK, Morgan R, et al. Assessment of cellular telephone and other radio frequency exposure for epidemiologic research. *Epidemiology* 1996; 7: 291.
- [16] Myung SK, Ju W, McDonnell DD, et al. Mobile phone use and risk of tumors: a meta-analysis. *J Clin Oncol* 2009; 27: 5565.
- [17] Corle C, Makale M, Kesari S. Cell phones and glioma risk: a review of the evidence. *J Neurooncol* 2012; 106: 1.
- [18] IARC monographs on the evaluation of carcinogenic risks to humans, IARC, Lyon 2013. Vol 102.
- [19] Inskip PD, Møller-Jensen L, Gridley G, Olsen JH. Incidence of intracranial tumors following hospitalization for head injuries (Denmark). *Cancer Causes Control* 1998; 9: 109.
- [20] Choi NW, Schuman LM, Gullen WH. Epidemiology of primary central nervous system neoplasms. II. Case-control study. *Am J Epidemiol* 1970; 91: 467.
- [21] Amirian ES, Zhou R, Wrensch MR, et al. Approaching a Scientific Consensus on the Association between Allergies and Glioma Risk: A Report from the Glioma International Case-Control Study. *Cancer Epidemiol Biomarkers Prev* 2016; 25: 282.
- [22] Ostrom QT, Adel Fahmideh M, Cote DJ, et al. Risk factors for childhood and adult primary brain tumors. *Neuro Oncol* 2019; 21: 1357.
- [23] Schlehofer B, Blettner M, Preston-Martin S, et al. Role of medical history in brain tumour development. Results from the international adult brain tumour study. *Int J Cancer* 1999; 82: 155.
- [24] Preston-Martin S, Mack WJ. Neoplasms of the nervous system. In: *Cancer Epidemiology and Prevention*, 2nd ed, Shottenfeld D, Fraumeni JF (Eds), Oxford University Press, New York 1996.
- [25] Bondy ML, Lustbader ED, Buffler PA, et al. Genetic epidemiology of childhood brain tumors. *Genet Epidemiol* 1991; 8: 253.