

Case Report

Renal Vein Thrombosis in Extremely Low Birth Weight Preterm Neonate & Utility of Bed Side Renal Doppler in NICU

Prakash C. Vaghela^{*}, Chirag Gabani, Hiral D. Mangukiya, Jatin Rajyaguru

Department of Neonatal Intensive Care Unit and Neonatology, Nice Children Hospital, Bhavnagar, Gujarat

Email address:

prakash_vghl@yahoo.co.in (Prakash C. Vaghela), gabani.chirag060@gmail.com (Chirag Gabani),

hirmangukiya154@gmail.com (Hiral D. Mangukiya), rajyaguru-jatin17@gmail.com (Jatin Rajyaguru)

^{*}Corresponding author

To cite this article:

Prakash C. Vaghela, Chirag Gabani, Hiral D. Mangukiya, Jatin Rajyaguru. Renal Vein Thrombosis in Extremely Low Birth Weight Preterm Neonate & Utility of Bed Side Renal Doppler in NICU. *American Journal of Pediatrics*. Vol. 8, No. 4, 2022, pp. 267-270.

doi: 10.11648/j.ajp.20220804.23

Received: June 28, 2022; **Accepted:** September 1, 2022; **Published:** December 15, 2022

Abstract: Renal vein thrombosis (RVT) is though common form of thromboembolism in neonates yet uncommon in extremely low birth weight pre-term neonates. Neonatal thromboembolism is more commonly associated with central venous catheter but we present a case report of an extremely low birth weight preterm with left side RVT which was not associated with central venous catheter and diagnosed by using bedside point of care renal ultrasound in the NICU. Though the incidence of RVT in adults and children is very low in Asian countries, its incidence, risk factors and final outcome in neonatal RVT may be different from other countries. Acquired as well as genetic risk factors are significantly contributors in thromboembolism in neonate and central venous lines are one of the most common acquired risk factor. However mortality rate associated with renal vein thrombosis is less than other forms of thrombosis in neonate but there is significant degree of short term as well as long term sequelae. Initiation of thrombus formation may be triggered by vascular trauma, decreased vascular blood flow, increased viscosity of blood, thrombophilia or hyper osmolality. The classical triad for the renal vein thrombosis includes thrombocytopenia, hematuria along with unilateral or bilateral mass in flank. We recognised the pitfalls in managing RVT in preterm neonates. RVT, though rare, should be considered in the differential diagnosis while managing a preterm with hematuria or sepsis. Renal venography is the gold standard test for diagnosis of RVT however bedside renal ultrasound is very useful & prompt in diagnosing & monitoring doppler flow in renal vessels in RVT in neonates. There are no evidence based clear guidelines for management of the disease.

Keywords: Renal Vein Thrombosis, Extremely Low Birth Weight, Pre-term Neonate, Bedside Renal Ultrasound

1. Introduction

Renal vein thrombosis has been first described in 1840 by Rayer. The exact incidence of RVT is undetermined but case reports have increased in last 3 decades. Renal vein thrombosis is little uncommon due to sepsis in extremely low birth weight pre-term neonates & far rare in non-catheter associates patients. But for the affected kidneys it has a very grave prognosis. Male neonates are more prone to develop RVT as compared to female in the presence of provoking risk

factors. We report a case of unilateral RVT in an extremely low birth weight preterm baby, which was diagnosed early using point of care renal ultrasound & D=doppler. RVT is often diagnosed late in the absence of bed side ultrasound & doppler. We have treated this unilateral RVT with LMWH for 6 weeks. The clinical presentation is rather silent initially and renal ultrasound with doppler imaging is very helpful in prompt diagnosis.

2. Case Report

A male neonate with an extremely low birth weight of 500gm & extremely preterm born at 24 weeks of gestation to a 24 year old primi gravida mother. Antenatally mother had recurrent per vaginal bleeding, severe oligohydramnios. During this pregnancy, the mother had leaking PV and chorioamnionitis at 24 weeks of gestation hence neonate was born prematurely, and her antenatal ultrasounds were all normal. Baby was admitted in the NICU with moderate RDS & early onset sepsis. At the age of 32 days, the infant had gross hematuria and palpable left renal mass. His investigations showed the following results: urine for blood showed 2+, protein 2+, RBC: 20-30/hpf, complete blood count revealed anaemia Hb: 7.2, thrombocytopenia (133000/cmm) along with urea, electrolytes, liver function test and coagulation profile were all within normal range. Protein C & S were normal. The C reactive protein was 9.46 mg/L, PCT: 2.79 ng/mL and the blood culture was negative. The doppler study of the middle cerebral artery

was normal. The echocardiogram was normal. Renal ultrasound with doppler was done, which showed that the left kidney was enlarged (49*28mm) with oedematous and hypoechoic thrombus in left renal vein along with thrombus in the inferior vena cava (Figure 1) with absent colour doppler flow in the left renal vein and reversal of the left renal arterial doppler flow (Figure 2) and supra-renal hypoechoic lesion. Right kidney measured 32*20mm and right renal vein appeared normal & showed normal colour doppler flow. The neonate was diagnosed to have the left RVT. The infant was managed with low molecular weight heparin (LMWH). Blood pressure was higher than the 95th percentile, so oral antihypertensive amlodipine started. Complete blood count, renal function, liver function & APTT, PT/INR were monitored throughout the course. We have treated this unilateral RVT with LMWH for 6 weeks and repeat renal ultrasound & renal doppler done which was suggestive of improved doppler in renal vein as well as in the artery (Figure 3) and baby was discharged successfully with weight of 1800 grams.

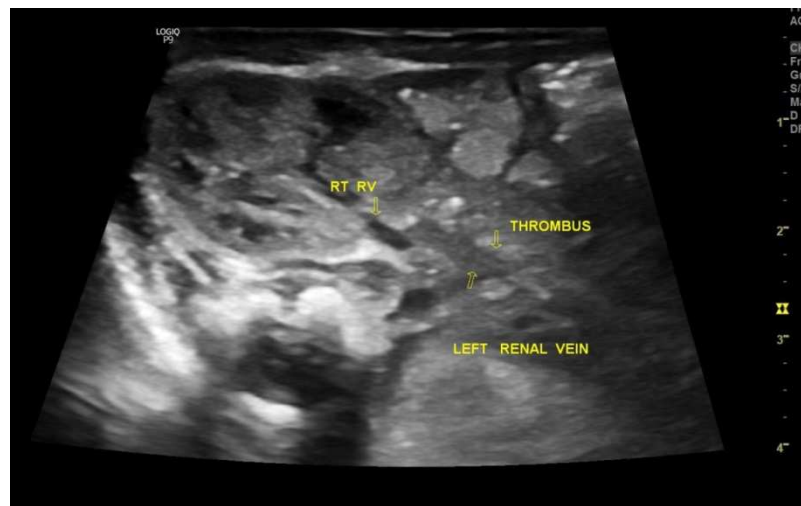

Figure 1. Thrombus in left renal vein

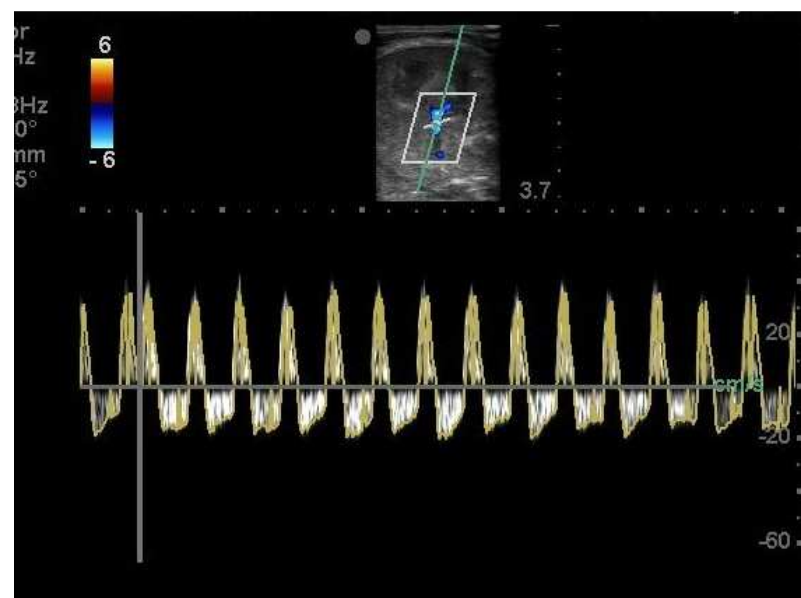


Figure 2. Reversal of left renal arterial doppler flow.

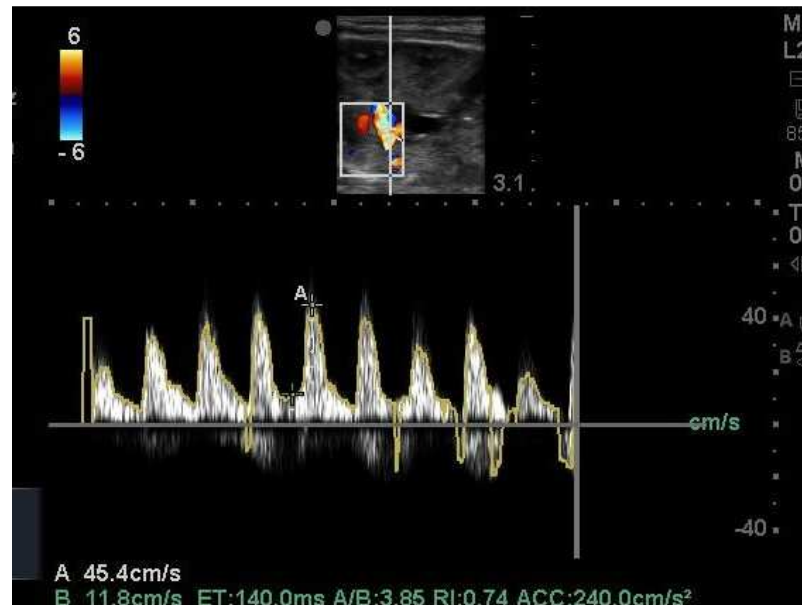


Figure 3. Improved doppler in left renal artery.

3. Discussion

Though neonatal thrombosis is very rare but renal vein thrombosis (RVT) is most common form in almost 15 to 20 % of total systemic thromboembolism. A median age for the presentation is around 2-3 days with unilateral renal vein involvement in 89-72% and bilateral renal vein involvement in 28-31% of cases [1, 2]. The clinical presentation of RVT in form of palpable enlarge kidney, macro or micro haematuria, thrombocytopenia and in case of bilateral RVT decreased urine output with or without renal failure. RVT in neonates is affected by multiple factors and it is often associated with coagulopathy disorders, maternal diabetes, perinatal asphyxia, sepsis, placement of central venous lines (CVL) and hereditary thrombophilic factors [3-5]. In neonates with RVT, not associated with CVL, usually thrombus formation starts in the small vessels of the kidney and from there it may extend into the renal vein and/or inferior vena cava. In neonates with RVT, associated with CVL, the thrombus formation mostly starts in the vessel adjacent to the CVL and then extended into the kidney [6]. On renal ultrasound, it shows either unilateral or bilateral kidney enlargement which is usually associated with loss of cortico-medullary differentiation and reduced or absent flow in the renal vein on doppler scan [7, 8]. Long-term functional complications are vary and include renal insufficiency, renal tubular dysfunction and hypertension in up to 30% of patients. Evidence based data on recommendations of appropriate clinical management as well as treatment of the neonates with RVT is lacking and no clear guidelines have been formed because of less data available [9-11]. However current data suggestive for unilateral RVT without renal impairment or extension of thrombus into the inferior vena cava, either:

- 1) Supportive care only with regular radiologic monitoring for extension of thrombus OR;

- 2) Anticoagulation therapy with unfractionated heparin (UFH)/ low-molecular-weight heparin (LMWH) in therapeutic doses rather than no therapy [11, 12].

For unilateral RVT with renal impairment or extension of thrombus into the inferior vena cava, anticoagulation with UFH for a total duration of between 6 weeks or LMWH for total duration of 3 months is suggested [13, 14]. For bilateral RVT with evidence of renal impairment, anticoagulation with UFH/LMWH or initial thrombolytic therapy with tissue plasminogen activator followed by anticoagulation with UFH/LMWH is suggested [13]. On other hand renal artery thrombosis (RAT) in the neonate is very rarely observed and far less common than RVT, and there is little data about its incidence. Common provoking factors for RAT are umbilical arterial catheters, patent ductus arteriosus and hereditary thrombophilia. The clinical presentation is rather silent and findings of renal ultrasound can be minimal and only renal doppler imaging is helpful as a non-invasive technique. Early diagnosis & therapy reduce adverse outcome [9, 15, 16]. The outcome is rather poor for affected kidney and often leads to global atrophy. For neonates with a peripheral arterial catheter-related thrombosis, immediate removal of the catheter and UFH anticoagulation with or without thrombolysis or surgical thrombectomy and microvascular repair with subsequent heparin therapy are suggested.

4. Conclusion

Successful management of RVT in preterm requires a timely and accurate diagnosis. The possibility of RVT should be suspected in the baby who had sepsis even in non-catheterised neonate & with normal coagulation profile. Renal doppler ultrasound is useful in making a diagnosis of RVT in neonates and should be considered early in the work-up & monitoring of a neonate with sepsis or any high risk neonate for thrombosis.

References

- [1] Motta, M. Neonatal renal venous and arterial thrombosis. *Ital J Pediatr* 41 (Suppl 1), A24 (2015).
- [2] Barbara Schmidt, Maureen Andrew; Neonatal Thrombosis: Report of a Prospective Canadian and International Registry. *Pediatrics* November 1995; 96 (5): 939–943. 10.1542/peds.96.5.939.
- [3] Bhat R, Kumar R, Kwon S, et al.: Risk Factors for Neonatal Venous and Arterial Thromboembolism in the Neonatal Intensive Care Unit-A Case Control Study. *J Pediatr*. 2018; 195: 28–32. 10.1016/j.jpeds.2017.12.015.
- [4] Lambert I, Tarima S, Uhing M, et al.: Risk Factors Linked to Central Catheter-Associated Thrombosis in Critically Ill Infants in the Neonatal Intensive Care Unit. *Am J Perinatol*. 2019; 36 (3): 291–295. 10.1055/s-0038-1667377.
- [5] Dubbink-Verheij GH, Pelsma ICM, van Ommen CH, et al.: Femoral Vein Catheter is an Important Risk Factor for Catheter-related Thrombosis in (Near-) term Neonates. *J Pediatr Hematol Oncol*. 2018; 40 (2): e64–e68. 10.1097/MPH.0000000000000978.
- [6] Moudgil A. Renal venous thrombosis in neonates. *Curr Pediatr Rev*. 2014; 10 (2): 101-6. doi: 10.2174/157339631002140513101845. PMID: 25088263.
- [7] van Ommen CH, Heijboer H, Büller HR, Hirasing RA, Heijmans HS, Peters M. Venous thromboembolism in childhood: a prospective two-year registry in The Netherlands. *J Pediatr*. 2001; 139 (5): 676-681.
- [8] Massicotte MP, Dix D, Monagle P, Adams M, Andrew M. Central venous catheter related thrombosis in children: analysis of the Canadian Registry of Venous Thromboembolic Complications. *J Pediatr*. 1998; 133 (6): 770-776.
- [9] Unal S, Gönülal D, Siyah Bilgin B, et al.: Experience and Prognosis of Systemic Neonatal Thrombosis at a Level III NICU. *J Pediatr Hematol Oncol*. 2018; 40 (7): e410–e414. 10.1097/MPH.0000000000001218.
- [10] El-Naggar W, Yoon EW, McMillan D, et al.: Epidemiology of thrombosis in Canadian neonatal intensive care units. *J Perinatol*. 2020; 40 (7): 1083–1090. 10.1038/s41372-020-0678-1.
- [11] Kayemba-Kay's S. Spontaneous neonatal renal vein thrombosis, a known pathology without clear management guidelines: An overview. *Int J Pediatr Adolesc Med*. 2020 Mar; 7 (1): 31-35. doi: 10.1016/j.ijpam.2019.07.001. Epub 2019 Jul 3. PMID: 32373700; PMCID: PMC7193072.
- [12] Monagle P, Chan AK, Goldenberg NA, Ichord RN, Journeycake JM, NowakGöttl U, Vesely SK: Antithrombotic therapy in neonates and children. Antithrombotic Therapy and Prevention of Thrombosis, 9th ed: American College of Chest Physicians Evidence-Based Clinical Practice Guidelines. *Chest* 2012, 141 (2 Suppl): e737S-801S.
- [13] Paul Monagle, Fiona Newall; Management of thrombosis in children and neonates: practical use of anticoagulants in children. *Hematology Am Soc Hematol Educ Program* 2018; 2018 (1): 399–404.
- [14] Goldenberg NA, Abshire T, Blatchford PJ, et al; Kids-DOTT Trial Investigators. Multicenter randomized controlled trial on Duration of Therapy for Thrombosis in Children and Young Adults (the Kids-DOTT trial): pilot/feasibility phase findings. *J Thromb Haemost*. 2015; 13 (9): 1597-1605.
- [15] Schmidt B, Andrew M. Neonatal thrombosis: report of a prospective Canadian and international registry. *Pediatrics*. 1995 Nov; 96 (5 Pt 1): 939-43. PMID: 7478839.
- [16] Kraft JK, Brandão LR, Navarro OM: Sonography of renal venous thrombosis in neonates and infants: can we predict outcome? *PediatrRadiol* 2011, 41: 299-307.