

Delayed Diagnosis of Congenital Hypothyroid: Concealed Problem in Developing Countries

Luh Putu Eka Sari Kresnandari, I Made Arimbawa*, I Made Darma Yuda*

Department of Pediatrics, Faculty of Medicine, Udayana University, Denpasar, Indonesia

Email address:

sarikresnandari@gmail.com (Luh Putu Eka Sari Kresnandari), maderimawa@gmail.com (I Made Arimbawa),

darmayuda.made@gmail.com (I Made Darma Yuda)

*Corresponding author

To cite this article:

Luh Putu Eka Sari Kresnandari, I Made Arimbawa, I Made Darma Yuda. Delayed Diagnosis of Congenital Hypothyroid: Concealed Problem in Developing Countries. *American Journal of Pediatrics*. Vol. 8, No. 3, 2022, pp. 181-184. doi: 10.11648/j.ajp.20220803.16

Received: July 13, 2022; **Accepted:** August 5, 2022; **Published:** August 24, 2022

Abstract: *Introduction:* Screening program of congenital hypothyroidism is one of crucial evaluation in newborn period, because early detection and prompt treatment can prevent mental retardation. This screening is quite simple, and the result was revealed quickly. Beside devastating effect to central nervous system, undiagnosed congenital hypothyroidism also affect skeleton and bone maturation. Hypothyroidism constitutes about 25-30% cases of short stature in the developing nations. *Case:* A 6 years-old female referred to the Sanglah General Hospital in December 2021 with short stature and delayed milestone of development. She cannot walk and talk like normal children in her age. Patient performed thyroid profile and it suggest hypothyroidism with low FT4 0,42 ng/dL and high level of TSH 119,79 IU/ml. Bone age revealed delayed in bone maturation according to girls 8 months age. Patient got levothyroxine with dosage 12 mcg/kg/day (100 mcg/day) in December 2021. After one months of treatment, thyroid profile showed improvement TSHs still above normal 16,36, FT4 was normal 0,78. *Conclusion:* There is still cases of delay diagnosis and treatment of CH in developing country due to lack of screening program in newborn, low parental education level which led to devastating outcome for neuro muscular development.

Keywords: Late Diagnosis, Congenital Hypothyroid, Outcome

1. Introduction

Hypothyroidism is an endocrine disorder caused by deficiency of thyroid hormone (thyroxin) which can affect peripheral tissues. Congenital Hypothyroidism (CH) is low level of thyroid hormone since at birth [1]. This abnormality is caused by defect in development of thyroid gland (dysgenesis) or a disorder of thyroid hormone biosynthesis. It classified as primary hypothyroidism, meanwhile secondary or central hypothyroidism results from a deficiency of thyroid stimulating hormone (TSH) [2].

Thyroid hormones play important role in mediating skeletal growth and maturation. This action through stimulates growth hormone (GH). Screening program of congenital hypothyroidism is one of crucial evaluation in newborn period, because early detection and prompt treatment can prevent mental retardation. It is detectable with simple and cost-benefit biochemical test in neonatal period.

The most severe effect of undiagnosed congenital hypothyroidism is on skeleton and bone maturation, also central nervous system as mental development [2]. Hypothyroidism constitutes about 25-30% cases of short stature in the developing nations [3]. Prior advancement of newborn screening programs, the incidence of congenital hypothyroidism, was diagnosed only by clinical feature, in the range of 1:7.000 to 1:10.000. Nowadays, the incidence was initially reported to be in the range of 1:3.000 to 1:4.000 [2]. Recently, thyroid hormone screening has become standard in many countries [2]. Unfortunately, newborn thyroid screening is not routinely implemented in Indonesia. This screening significantly reduced neurodevelopment damage also reversed the chances of growth failure during infancy and early childhood [2, 4].

In Indonesia, based on data of CH in Dr. Cipto Mangunkusumo Hospital in Jakarta, and Hasan Sadikin Hospital in Bandung, the incidence of CH around 2000 to 2014, was 1:2.513 from 213.669 that were screened [1].

Permanent mental deficit was found in almost 70% of CH cases who were diagnosed at the age older than one year [1]. Low educated parents are often unaware of the importance of early diagnosis and commencement of therapy for CH [5]. Late identification and diagnosis of congenital hypothyroidism, leading to delay proper management that will impair mental development and physical growth. We present a case of developmental delay which further noticed as delayed diagnosis of hypothyroid.

2. Case

A 6 years-old female referred to the Sanglah general hospital in December 2021 with short stature and delayed milestone of development. She cannot walk and talk like normal children in her age. Her mother told that when she 3 years old she has difficulty to defecate and had abdominal distention. Sometimes she need laxative per rectal to defecate. She had visited public health center in her district regularly and already measured for anthropometric status in every admission, but her mother said there is no specific information and management to her child. The anthropometric status show that her weight/age at the first two month after birth still on normal range but later measurement show decline in growth pattern to below third percentile when she was 18 months old.

There was no history of mother prenatal illness. She was born full term by vaginal delivery with a birth weight of 3,5 kg and length 49 cm. She only got formula milk. Her mother said that she could eat solid food after 2 years old. She can hold her head after 2 years old and sit with support in 4 years old. She only could say syllables not words. On physical examination, patient is alert, blood pressure 90/60 mmHg, pulse rate 90 beat per minute, respiratory rate 22 times per minute, normal body temperature. She had microcephaly 46 cm (below 3 SD according nellhaus head circumference), coarse facial features, narrow palpebral fissure, depressed nasal bridge. There is no goiter. Abdomen is distended without umbilical hernia. Tonus is still normal.

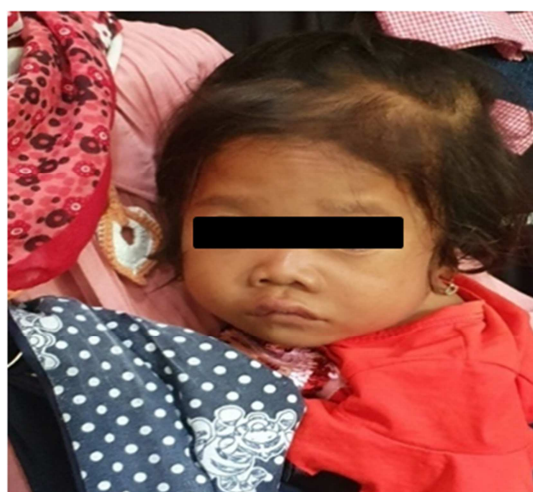

Figure 1. Coarse face, depressed nasal bridge.

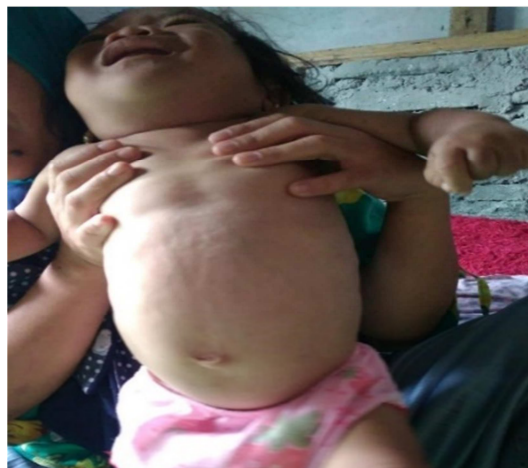

Figure 2. Abdominal distention.

Her anthropometry was still of infantile proportion with a length of 67 cm (height for age below 3rd percentile of CDC or <-3SD according WHO growth chart), weight of 7,8 kg (weight for age was below 3rd percentile of CDC and <-3 SD according WHO growth chart), BMI was 17,3 kg/m² (0-1 SD), upper and lower segment ratio 1.6:1. Measurement of genetic potential height is around 133-150 cm, mid parental height was is 142 cm and her height is below these potential genetic.

Patient performed thyroid profile and it suggest hypothyroidism with low FT4 0,42 ng/dL and high level of TSH 119,79 IU/ml. Bone age revealed delayed in bone maturation according to girls 8 months age.

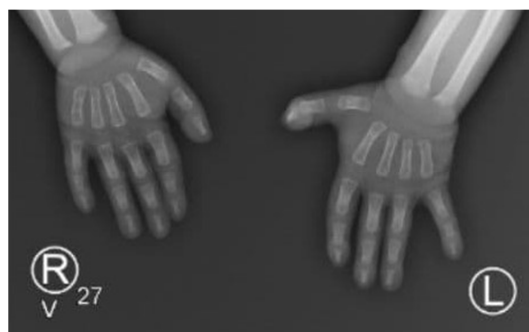


Figure 3. Bone age.

Patient got levothyroxine with dosage 12 mcg/kg/day (100 mcg/day) since December 2021. After one months of treatment, thyroid profile showed improvement TSHs still above normal 16,36 IU/mL and FT4 was normal 0,78 ng/dL. The consecutive months, thyroid profile showed TSHs was 6,36 IU/mL (decreased than previous month) and FT4 was on normal limit 0,92 ng/dL. Evaluation for intelligence quotient (IQ test) by using Wechsler Intelligence Scale for Children (WISC IV) aged 6-16 years showed value 60 (extremely low) according to the age.

3. Discussion

Congenital hypothyroidism (CH) is Congenital

Hypothyroidism (CH) is low level of thyroid hormone since at birth [1]. This abnormality is caused by defect in development of thyroid gland (dysgenesis) or a disorder of thyroid hormone biosynthesis. Further, it is classified into permanent and transient CH. Permanent CH refers to a persistent deficiency of thyroid hormone that requires life-long treatment. Transient CH is deficiency of thyroid hormone, discovered at birth, but then recovering to normal and treatment can be last in few months [2]. Vast majority of permanent CH is caused by thyroid dysgenesis. Mostly, it is caused by ectopic thyroid gland location, remaining cases caused by absent or incomplete development of thyroid gland tissue which termed aplasia or hypoplastic gland. Rest cause (15% cases) are thyroid hormone synthesis/production defect, which is termed as thyroid dyshormogenesis. Several literature state these defects are inherited through autosomal recessive pattern and related to genes mutations [1]. Transient congenital hypothyroidism caused by maternal or neonatal excess iodine exposure, maternal or neonatal iodine deficiency, maternal consumption of antithyroid drugs, a maternal antibody which block TSH receptor [1]. Antithyroid drugs which is consumed by hyperthyroid mothers may inhibit the synthesis of fetal thyroid hormone. This effect can last from several days to several weeks after birth. The other mechanism of transient CH is crossing maternal antithyroid antibodies through the placenta can block thyroid TSH receptors in neonatal. It last around three to six months after birth as the maternal antibody levels decline [1].

Diagnosis of congenital hypothyroidism is confirmed by decreased levels of serum thyroid hormone (total or free T4) and elevated levels of thyroid-stimulating hormone (TSH) [6]. Congenital hypothyroid are often show subtle clinical manifestations, and many newborn infants remain undiagnosed at birth. This condition is due to protective effect from maternal thyroid hormone which can reserve fetal brain function. The most common signs are umbilical hernia, macroglossia, poor feeding, large fontanelle, and cold/mottled skin [7]. Other malformations include spiky hair, cleft palate, neurologic abnormalities, and genitourinary malformations [2]. In this case, patient had born vigorously with normal birth weight 3500 grams, 49 cm of length. At the perinatal period, her mother said there were no abnormality noticed. After 2 months old she had deterioration of weight which is demonstrated on her growth chart. Thyroid level when she attends endocrine polyclinic revealed low level of FT4 and high level of TSH confirming diagnosis of hypothyroid.

Principal problem in this case report is delayed in diagnosis of CH. Many factors contribute to delayed diagnosis such as uneducated or low education level of parent, non-specific symptoms in early life and political issue which make screening program not widely applied in Indonesia. Most infants with CH are asymptomatic at birth. Screening programs in newborn, play an important role for the early detection of CH in apparently healthy newborn infants. Before the screening programs were implemented, CH were diagnosed clinically, and the reported incidence

was considerably lower, varying from 1:7000 to 1:10.000 [2]. Study conducted in Danish showed that 10% of affected children were diagnosed clinically during their first month of life, 40% in the first 3 months, and 70% by the age of 1 year. The remaining cases were not diagnosed until their third or fourth years of life [8]. A retrospective analysis of 1.000 cases of CH followed in Pediatric endocrinology Unit at Hacettepe university Children's found that the mean age at clinical diagnosis was 49 months. About 3.1% of the cases were diagnosed during the neonatal period and 55.4% were diagnosed after 2 years of age [9]. In Indonesia, CH screening was not a routine, government-sponsored program before 2006 [10]. In this case, at first patient was referred to growth and development polyclinic due to developmental delay. After initial history taking and physical examination, we got that patient has several abnormalities such as history of constipation when she was 3 years old, lack of activity, failure to thrive, coarse facies and disproportionate body height. The parents already had regular visit to district hospital, but it was seen the health care workers were unaware of these clinical features, so they did not do further investigation like thyroid evaluation.

In early years, initial recommended levothyroxine (LT4), dose for treating CH were in 5 - 7µg/kg/day range. Recently 10 - 15µg/kg/day was recommended by the American academy of pediatrics [11, 12]. Episodes of overtreatment during the first six months of CH treatment period may be a risk factor for sustained attention and inhibitory control at school age [13]. In the other hand, study conducted by Rovet et al showed that children receiving a higher starting dose of LT4 were reported to have better learning ability at the expense of more behavior problems [14]. In this case, patient had already lost golden period of brain development, but the purpose of therapy is not only to preserve brain function but also to maintain metabolic function such as controlling energy storage and expenditure.

One of devastating effect of untreated congenital hypothyroidism is mental retardation. Timing of therapy is crucial to neurologic outcome. Several studies show there is an inverse relationship between intelligence quotient (IQ) and the age at diagnosis [2]. There are reports CH children who were diagnosed at neonatal screening program still had mild neurocognitive impairment, reduced intelligence quotient (IQ) and problems with behavior and attention, as well as subtle fine motor, language, and visuospatial impairment [15-18]. In this case, after 2 months of therapy we performed IQ test by using WISC IV showed value about 60 (extremely low IQ) even though FT4 value already reached normal level.

Physical impairment of linear growth and bone maturation also occurs in untreated CH. Combine manifestation between physical and neurologic problem whose treatment is delayed can show spasticity and gait abnormalities, dysarthria or mutism, and autistic behavior [19]. These cognitive and motor deficits will affect the quality of life, social life, emotions, behavior, and self-esteem of this patient. In this case, we have already

evaluated for PEDS QL according to parent report with score 41,1 (disturbance of quality of life). Rochmah et al, age at first treatment, initial dose of levothyroxine and length of treatment are correlated with quality of life in children with congenital hypothyroidism [20].

Several studies have already evaluated about relationship between late diagnosis of CH and final height. Kardenim and Yodam, 2001 studied hypothyroidic children who had been diagnose lately still cannot reach their final height even catch-up spurt after therapy. Prolonged hypothyroidism may result in compromised adult height in some patients. Several factors contribute to height deficit in CH children namely the duration of disease, the height deficit at the time of the diagnosis, etiological differences, and retardation for catch-up growth [21]. In this case, patient was diagnosed at the age 6-year-old, height for age at the onset of diagnosis below -3 SD, still unknown in etiology.

4. Conclusion

There is still cases of delay diagnosis and treatment of CH in developing country due to lack of screening program in newborn, low parental education level which led to devastating outcome for neuro muscular development.

Conflict of Interest

All the authors do not have any possible conflicts of interest.

References

- [1] Kurniawan LB. Congenital Hypothyroidism: Incidence, Etiology and Laboratory Screening. *Indones J Clinical Pathol Med Laboratory*. 2020; 26 (3): 375 – 80. doi: <https://dx.doi.org/10.24293/ijcpml.v26i3.1527>
- [2] Rastogi MV, LaFranchi SH. Congenital hypothyroidism. *Orphanet J Rare Dis*. 2010; 10; 5: 17. doi: <https://doi.org/10.1186/1750-1172-5-17>
- [3] Chowdhury SP, Sarkar TK, Haldar D, Taraphdar P, Naskar TK, Sarkar GN. Short stature in children: Experience from a tertiary care hospital in Kolkata, India. *The health*. 2011; 2: 139-42.
- [4] Ranke MB, Schwarze CP, Mohnike K, von Mühlendahl KE, Keller E, Willgerodt H, et al. Catch-up growth after childhood-onset substitution in primary hypothyroidism: Is it a guide towards optimal growth hormone treatment in idiopathic growth hormone deficiency. *Horm Res*. 1998; 50: 264-70. doi: 10.1159/000023288.
- [5] Malik BA, Butt MA. Is delayed diagnosis of hypothyroidism still a problem in Faisalabad, Pakistan. *J Pak Med Assoc*. 2008; 58: 545-9.
- [6] Hamid F, Islam R., Paul N, Nusrat N. Congenital Hypothyroidism: A Severely Neglected Case Report in Bangladesh. *Bangladesh Medical Journal*. 2014; 41 (1): 59–61. <https://doi.org/10.3329/bmj.v41i1.18787>
- [7] Pulungan AB, Annisa D. 2019. Permasalahan dalam skrining hipotiroid. *Prosiding 7th Indonesian Pediatric Endocrinology Update*. Semarang.
- [8] Jacobsen BB, Brandt NJ. Congenital hypothyroidism in Denmark. *Arch Dis Child*. 1981; 56: 134-6. doi: 10.1136/adc.56.2.134.
- [9] Tarim OF, Yordam N. Congenital hypothyroidism in Turkey: a retrospective evaluation of 1,000 cases. *Turk J Pediatr*. 1992; 34: 197-202.
- [10] Ihsan I, Rini E. Delayed diagnosis of congenital hypothyroidism in an adolescent result in avoidable complications: a case report. *PI*. 2017; 57 (2): 108-6. doi: 10.14238/pi57.2.2017.108-16.
- [11] Ehrlich RM. Thyroxine dose for congenital hypothyroidism. *Clin Pediatr*. 1995; 34 (10): 521–22. doi: 10.1177/000992289503401002.
- [12] Rovet J. Congenital hypothyroidism: treatment and outcome. *Curr Opin Endocrinol*. 2005; 12 (1): 42–52. doi: 10.1186/1750-1172-5-17.
- [13] Alvarez M, Iglesias Fernandez C, Rodriguez Sanchez A, Dulin L, Iiguez E, Rodriguez Arnao MD. Episodes of overtreatment during the first six months in children with congenital hypothyroidism and their relationships with sustained attention and inhibitory control at school age. *Horm Res Paediatr*. 2010; 74 (2): 114–20. doi: 10.1159/000313370.
- [14] Rovet JF, Ehrlich R. Psychoeducational outcome in children with early-treated congenital hypothyroidism. *Pediatrics*. 2000; 105: 515–22. doi: 10.1159/000313370.
- [15] Oerbeck B, Sundet K, Kase BF, Heyerdahl S. Congenital hypothyroidism: influence of disease severity and L-thyroxine treatment on intellectual, motor, and school-associated outcomes in young adults. *Pediatrics*. 2003; 112: 923–930. doi: 10.1542/peds.112.4.923.
- [16] Kempers MJE, van der Sluijs Veer L, Nijhuis-van der Sanden RWG, et al. Neonatal screening for congenital hypothyroidism in The Netherlands: cognitive and motor outcome at 10 years of age. *J Clin Endocrinol Metab*. 2007; 92: 919–924. doi: 10.1210/jc.2006-1538.
- [17] Dimitropoulos A, Molinari L, Etter K, et al. Children with congenital hypothyroidism: long-term intellectual outcome after early high dose treatment. *Pediatr Res*. 2009; 65: 242–248. doi: 10.1203/PDR.0b013e31818d2030.
- [18] Rovet J. Long-term neuropsychological sequelae of early-treated congenital hypothyroidism: effects in adolescence. *Acta Paediatr*. 1999; 88: 88 –95. doi: 10.1111/j.1651-2227.1999.tb01168.x.
- [19] Bhattacharya A. Congenital hypothyroidism and developmental difficulties. *Gen Med*. 2013; 1: 1. doi: 10.4172/2327-5146.1000103.
- [20] Rochmah N, Faizi M, Dewanti C, Suryawan A. Pediatric quality of life in congenital hypothyroidism: an Indonesian study. *Int J Thyroidol*. 2020; 13 (2): 150-154. doi: 10.11106/ijt.2020.13.2.150.
- [21] Kandemir N, Yordam N. Height prognosis in children with late-diagnosed congenital hypothyroidism. *Turk J Pediatr*. 2001; 43 (4): 303-306.