



# Blood Purification Technology in the Treatment of Type Ia Glycogen Storage Disease Complicated with Severe Lactic Acidosis: A Case Report and Literature Review

Yu Luo, Fang Yang\*, Ding Liu, Zhiqiang Guo, Chongfeng Chen

Pediatrics, The First Affiliated Hospital of Jinan University, Guangzhou, China

**Email address:**

1002117792@qq.com (Yu Luo), tyf@jun.edu.cn (Fang Yang)

\*Corresponding author

**To cite this article:**

Yu Luo, Fang Yang, Ding Liu, Zhiqiang Guo, Chongfeng Chen. Blood Purification Technology in the Treatment of Type Ia Glycogen Storage Disease Complicated with Severe Lactic Acidosis: A Case Report and Literature Review. *American Journal of Pediatrics*.

Vol. 7, No. 4, 2021, pp. 229-233. doi: 10.11648/j.ajp.20210704.19

**Received:** November 28, 2021; **Accepted:** December 15, 2021; **Published:** December 29, 2021

---

**Abstract:** Glycogen storage disease type Ia is a genetic disease caused by glucose-6-phosphatase deficiency, which often causes hypoglycemia, hyperuricemia, hypertriglyceridemia, and lactic acidemia. Severe lactic acidosis is a serious complication of glycogen storage disease type Ia. This study aimed to analyze the clinical features and treatment of glycogen storage disease type Ia with severe lactic acidosis. We performed a retrospective analysis of the diagnosis and treatment of a patient with glycogen storage disease type Ia with severe lactic acidosis admitted to our department during the COVID-19 period and reviewed the related literature. The patient was admitted to our hospital for chest pain and vomiting of three days duration, which was accompanied by dyspnea for five hours. The patient has had a type Ia glycogen storage disease for 11 years, and arterial blood gas analysis revealed a pH of 7.192 and lactic acid levels of 26.77 mmol/L. However, the patient was diagnosed with type Ia glycogen storage disease alongside severe lactic acidosis. After 4 hours of hemodialysis and 36 hours of continuous blood purification, the patient had no shortness of breath, dyspnea, nausea, or vomiting. Biochemical retesting indicated a pH of 7.482, lactic acid levels of 7.41 mmol/L, and blood glucose levels of 10.7 mmol/L. Glycogen storage disease type Ia can lead to life-threatening severe lactic acidosis. Continuous renal replacement therapy is an effective treatment for severe lactic acidosis. Therefore, as prevention and control are being carried out during the COVID-19 period, attention should be given to the treatment of special populations, such as those with glycogen storage disease to prevent serious complications.

**Keywords:** Glycogen Storage Disease, Lactic Acidosis, Continuous Renal Replacement Therapy

---

## 1. Introduction

Glycogen storage disease type I (GSD-I) is an autosomal recessive disease. Type Ia caused by G6PC gene mutation is the most common type [1, 2]. Glucose 6-phosphatase deficiency causes glucose 6-phosphate not to be metabolized into glucose, but instead into pyruvate, which is further decomposed into lactic acid, resulting in the increase of lactic acid level [3]. Failure to eat on time can cause hypoglycemia, resulting in hyperlactatemia and metabolic acidosis [4]. Raw corn starch is widely used by patients as a therapeutic diet [5]. The patient did not eat raw corn starch on time, resulting in hypoglycemia and lactic acidosis. Studies have found that

lactate concentration is directly proportional to mortality [6]. CRRT can treat lactic acidosis [7]. Blood purification techniques significantly reduced lactate levels compared with traditional methods [8]. Steunenbergh [9] found that early continuous blood purification can reduce mortality and improve prognosis. The level of lactic acid in this patient decreased significantly after HD and CRRT, suggesting that this kind of severe lactic acidosis can be treated with blood purification technology.

## 2. Case Report

An 11-year-old female was admitted to our department on July 13, 2020, due to chest pain and vomiting for three days, which was accompanied by dyspnea for five hours. In 2009, the patient was diagnosed with glycogen storage disease type Ia through genetic testing at the Peking Union Medical College Hospital. After the diagnosis, she was treated with raw corn starch, and her blood sugar level was controlled at 5.0-6.0 mmol/L. Recently, due to the requirements for prevention and control of the COVID-19, family members of children could not enter the campus to supervise their children's diet. The children ate irregularly during school with raw corn starch less frequently. On July 10, 2020, the patient developed chest pain, mainly under the xiphoid process with vomiting about four episodes per day, which was non-projectile with stomach contents. At about 15:00 on the 13th of July 2020, the patient developed dyspnea, which manifested as shortness of breath with low-grade fever. Since the onset of illness, the patient has had listlessness, poor appetite, loose stools of about two episodes per day, and a reduction in urine output. There was no family history of any genetic disease.

Physical examination findings on admission included body temperature (37.9°C), breathing rate (45 beats/minute), heart rate (160 beats/minute), blood pressure (125/60 mmHg), blood oxygen saturation (99%), weight (29 Kg), height (130 cm), and listlessness. The wing of the nose was incited. There was a mild triple concave sign, coarse breath sounds in both lungs, and no sounds of dry and wet rales. The heart was not enlarged, the xiphoid process was tender, the abdomen was distended, and the liver was 11 cm below the costal margin with medium quality, smooth surface, and neat edges. The spleen was not palpable.

After the admission, the arterial blood gas and biochemical examination findings revealed: residual alkali; -22.0 mmol/L, buffer base; -24.7 mmol/L, anion gap; 45.1 mmol/L, actual bicarbonate; 3.5 mmol/L, PH; 7.192, serum potassium; 4.34 mmol/L, glucose; 5.6 mmol/L, lactate; 26.77 mmol/L.

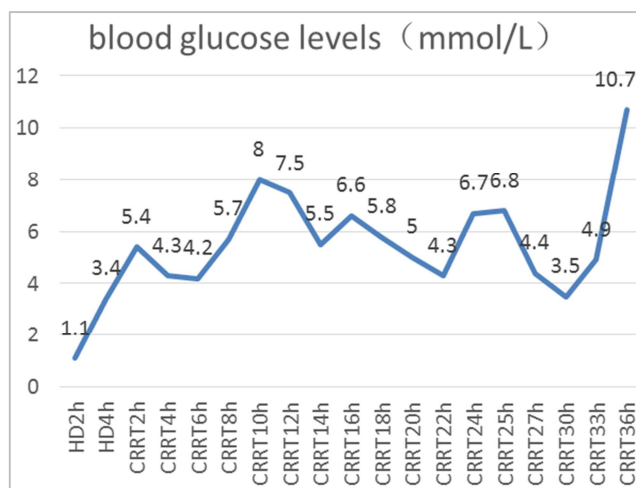
## 3. Final Diagnosis

Based on the patient's clinical features of chest pain, vomiting, and dyspnea blood gas analysis revealed severe lactic acidosis, combined with a previous history of type I glycogen storage disease she was diagnosed with type Ia glycogen storage disease and severe lactic acidosis.

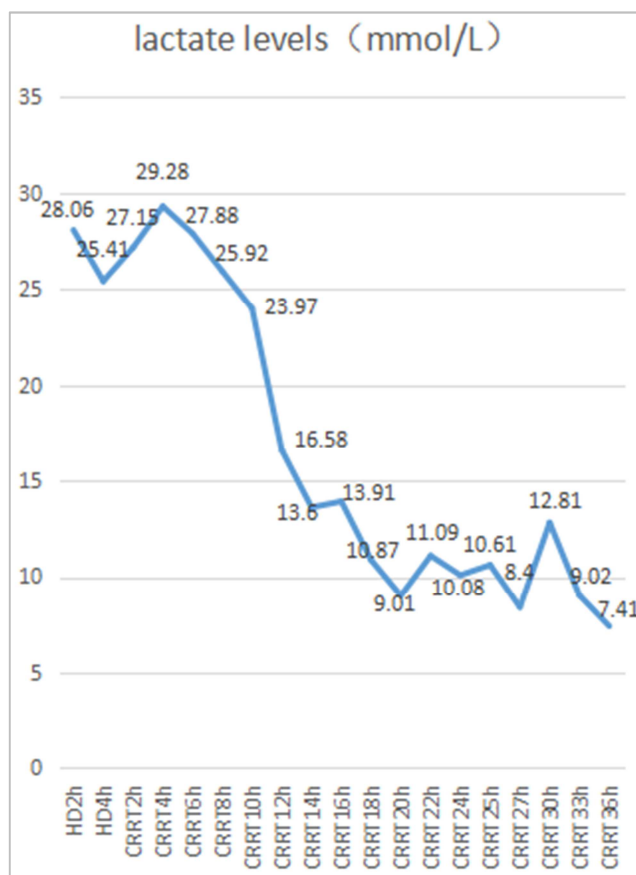
## 4. Therapy

When oxygen, bicarbonate, and other treatments were administered, the arterial blood gas indicated residual alkali; -23.6 mmol/L, buffer base; -25.6 mmol/L, anion gap; 47.9 mmol/L, actual bicarbonate; 4.4 mmol/L, PH; 7.077, serum potassium; 4.14 mmol/L, and glucose: 3.7 mmol/L. She had hemodialysis (HD) for four hours and continuous renal replacement therapy (CRRT) was given immediately for 36 hours. The blood glucose levels (insert figure 1,), lactate levels

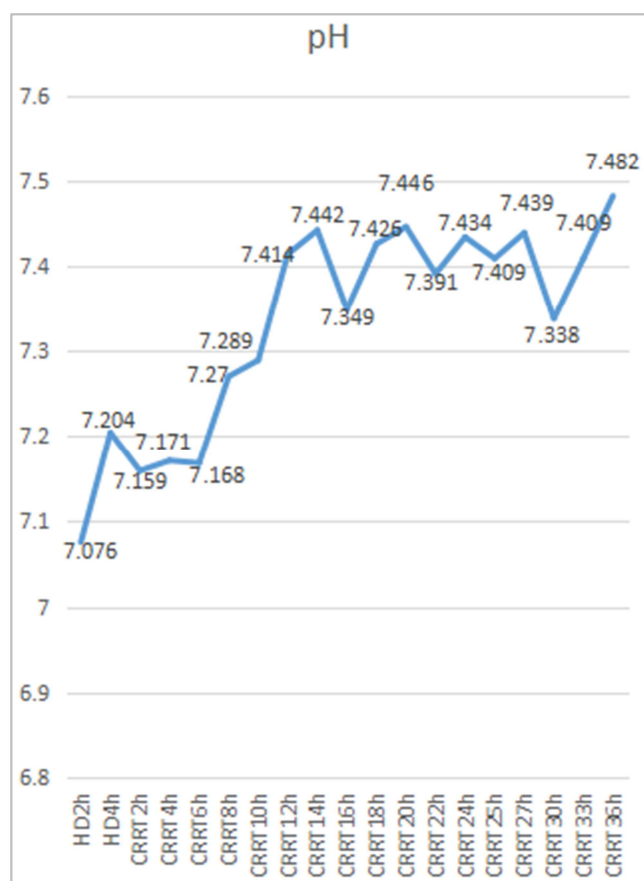
(insert figure 2), and changes in pH (insert figure 3) were measured every 1-3 hours during the dialysis. At the same time, dextrose and bicarbonate were adjusted, according to the monitored values. After the dialysis, the arterial blood gas showed pH; 7.482 and lactate; 7.41 mmol/L.



**Figure 1.** Changes in blood glucose levels at 4 hours of hemodialysis and 36 hours of continuous renal replacement therapy.



**Figure 2.** Changes in lactate levels at 4 hours of hemodialysis and 36 hours of continuous renal replacement therapy.



**Figure 3.** Changes in pH between 4 hours of hemodialysis and 36 hours of continuous renal replacement therapy.

## 5. Discussion

Glycogen storage disorder type I (GSD-I) is an autosomal recessive disease that was first described by Von Gierke in 1929 [10]. There are four subtypes: Ia, Ib, Ic, and Id with the most common caused by a mutation in the gene G6PC. The gene encodes glucose-6-phosphatase (G6Pase), containing 357 amino acids. The G6PC mutations lead to obstruction of gluconeogenesis and glycogenesis and disruption of glucose homeostasis, which often manifest clinically as hypoglycemia, hepatomegaly, hyperuricemia, hypertriglyceridemia, and lactic acidemia; long-term consequences include short stature, gout, osteoporosis, chronic renal failure, and hepatocellular adenomas and others [1, 2]. The lack of glucose-6-phosphatase results in the inability to hydrolyze glucose-6-phosphate to glucose and glucose-6-phosphate accumulation within the cytoplasm results in the build-up of glycogen [11, 12]. The lack of this enzyme leads to the metabolism of the glucose-6-phosphate glycolytic pathway to pyruvate, which is further decomposed into lactate, catalyzed by lactate dehydrogenase, resulting in increased lactic acid levels and even lactic acidosis [3].

Type Ia glycogen storage disease can be initially diagnosed based on clinical manifestations and blood biochemical test results; oral glucose tolerance test or glucagon stimulation test can assist in the diagnosis. The measurement of G6PC activity

in the liver tissue and detection of the G6PC gene is the gold-standard methods for diagnosis [13]. Prolonged feeding time in children with this disease can cause hypoglycemia, leading to hyperlacticaemia and metabolic acidosis. Regular detection of blood glucose is beneficial to the control of the disease, and lactic acid testing has a complementary role in the diagnosis of hypoglycemia. Glucose treatment is the first choice for complications of metabolic disorders in glycogen storage disease, an intravenous infusion of 10% glucose at 3.5 ml/kg is recommended for patients 6-12 years old to combat the symptoms caused by hypoglycemia [4]. If blood gas analysis indicates lactic acidemia, it is recommended to take sodium bicarbonate 1-2 mg/kg/d four times daily [4, 5]. As prolonged eating time is prone to hypoglycemia, it is recommended that infants and children fast for not more than 3-4 hours and adolescents no more than 5-6 hours. Raw cornstarch was the earliest diet recommended for treatment and it is currently used widely by patients to avoid hypoglycemia [5]. However, the survey report of Steunenberg [14] shows that the incidence of hypoglycemia in the treatment of type Ia glycogen storage with raw cornstarch accounted for 42% and hospitalization accounted for 31%, suggesting that attention should be paid to complications caused by improper dietary management, especially in children under the age of 12. Complications can result from failure to comply with the doctor's diet or the family members' inability to prepare the diet promptly.

The major cause of lactic acidosis can be divided into disorders associated with tissue hypoxia (type A), which includes shock, heart failure, severe hypoxemia, serious anemia, etc. and disorders with absent tissue hypoxia (Type B), which includes diabetes, tumors, congenital metabolic diseases, and others [7]. The patient was complicated with lactic acidosis due to congenital metabolic disease. Lactic acidosis is defined as serum pH < 7.35 and serum lactate level > 5 mmol/L. An acidic environment can have adverse effects on the respiratory, circulation, and nervous system, which can be manifested as hyperventilation, dyspnea, tachycardia or bradycardia, and others [15]. The higher the lactate concentration, the higher the mortality rate [6]. For the etiology of treatment, maintaining hemodynamic stability, maintaining appropriate oxygen pressure, intravenous sodium bicarbonate, or using bicarbonate during dialysis, especially CRRT treatment are all beneficial to the reduction of lactate acid levels. The target is to reduce the levels of lactate to the normal range [7].

Bicarbonate is a controversial drug in the treatment of lactic acidosis. It has no significant effect on improving hemodynamics and there may be a risk of volume overload, hypernatremia or hyperosmolality, reduction of ionized calcium, and aggravation of acidosis [16]. Bicarbonate-containing kidney replacement therapy can eliminate these adverse effects while removing lactic acid and controlling the symptoms.

The CRRT treatment can continuously and slowly remove water and solutes by diffusion, convection, and adsorption. The treatment of CRRT is not limited to renal diseases but also

extends to the treatment of non-renal diseases in acute and critical diseases, including sepsis or septic shock, drug poisoning, severe hydroelectrolyte, and acid-base metabolism disorders, lactic acidosis, and others [17].

As a small molecule, lactic acid can pass through the blood filter [18]. A Meta-analysis comparing the effects of conventional methods and blood purification techniques on lactic acid clearance found that blood purification techniques significantly reduced the level of lactic acid than conventional methods [8]. Early continuous blood purification can reduce the mortality rate, and improve the prognosis [9]. It has been shown that hemodialysis (HD), hemodiafiltration (HDF), and continuous venovenous hemofiltration (CVVH) can treat lactic acidosis. Compared with HD and HDF, CVVH has the following advantages: 1) little effect on hemodynamics; 2) the continuous and slow removal of lactic acid controls blood sugar within a reasonable range, corrects electrolyte disorders and acid-base balance disorders; 3) the range of alkali supplementation is being expanded relatively, and 4) little effect on the partial pressure of oxygen and blood oxygen saturation [19]. Experts recommend that lactic be measured every 2~6h during treatment [20]. Glycogen storage disease complicated with lactic acidosis is rarely reported. However, It has been reported that after the correction of shock and renal insufficiency, although dialysis was not used, serum lactic acid was effectively controlled [21].

## 6. Conclusion

Glycogen storage disease type Ia can lead to life-threatening severe lactic acidosis. In this report, the lactic acid levels and pH values of this patient were significantly improved after HD with CRRT, suggesting that blood purification technology treatment is an effective treatment modality for this type of severe lactic acidosis. This was precise because the family members could not effectively supervise the child's diet during the COVID-19 control period. Thus, the patient did not take raw cornstarch regularly, which caused hypoglycemia complicated by severe lactic acidosis. Therefore, as prevention and control are being carried out during the COVID-19 period, attention should be given to the treatment of special populations, such as those with glycogen storage disease to prevent serious complications.

## References

- [1] Chou, J. Y., Jun, H. S., & Mansfield, B. C. (2010). Glycogen storage disease type I and G6Pase- $\beta$  deficiency: etiology and therapy. *Nature reviews. Endocrinology*, 6 (12), 676–688. <https://doi.org/10.1038/nrendo.2010.189>.
- [2] Chou, J. Y., Matern, D., Mansfield, B. C., & Chen, Y. T. (2002). Type I glycogen storage diseases: disorders of the glucose-6-phosphatase complex. *Current molecular medicine*, 2 (2), 121–143. <https://doi.org/10.2174/1566524024605798>.
- [3] Wolfsdorf, J. I., & Weinstein, D. A. (2003). Glycogen storage diseases. *Reviews in endocrine & metabolic disorders*, 4 (1), 95–102. <https://doi.org/10.1023/a:1021831621210>.
- [4] Rake, J. P., Visser, G., Labrune, P., Leonard, J. V., Ullrich, K., Smit, G. P., & European Study on Glycogen Storage Disease Type I (ESGSD I) (2002). Guidelines for management of glycogen storage disease type I - European Study on Glycogen Storage Disease Type I (ESGSD I). *European journal of pediatrics*, 161 Suppl 1, S112–S119. <https://doi.org/10.1007/s00431-002-1016-7>.
- [5] Kishnani, P. S., Austin, S. L., Abdenur, J. E., Arn, P., Bali, D. S., Boney, A., Chung, W. K., Dagli, A. I., Dale, D., Koeberl, D., Somers, M. J., Wechsler, S. B., Weinstein, D. A., Wolfsdorf, J. I., Watson, M. S., & American College of Medical Genetics and Genomics (2014). Diagnosis and management of glycogen storage disease type I: a practice guideline of the American College of Medical Genetics and Genomics. *Genetics in medicine: official journal of the American College of Medical Genetics*, 16 (11), e1. <https://doi.org/10.1038/gim.2014.128>.
- [6] Nichol, A. D., Egi, M., Pettila, V., Bellomo, R., French, C., Hart, G., Davies, A., Stachowski, E., Reade, M. C., Bailey, M., & Cooper, D. J. (2010). Relative hyperlactatemia and hospital mortality in critically ill patients: a retrospective multi-centre study. *Critical care (London, England)*, 14 (1), R25. <https://doi.org/10.1186/cc8888>.
- [7] Kraut, J. A., & Madias, N. E. (2014). Lactic acidosis. *The New England journal of medicine*, 371 (24), 2309–2319. <https://doi.org/10.1056/NEJMr1309483>.
- [8] Huang Haiyan, Zhang Minjie, Yin Yuliang, Zheng Xinglong & Zhang Lilian. (2021). Removal of blood lactic acid by blood purification versus by conventional treatment in lactic acidosis patients: a meta analysis (China Blood Purification (01), 19-23. Doi: CNKI: Sun: zgjh.0.2021-01-005.
- [9] Sık, G., Demirbuga, A., Günhar, S., Nisli, K., & Citak, A. (2019). Clinical Features and Indications Associated with Mortality in Continuous Renal Replacement Therapy for Pediatric Patients. *Indian journal of pediatrics*, 86 (4), 360–364. <https://doi.org/10.1007/s12098-019-02868-w>.
- [10] Parikh, N. S., & Ahlawat, R. (2021). Glycogen Storage Disease Type I. In *StatPearls*. StatPearls Publishing.
- [11] Froissart, R., Piraud, M., Boudjemline, A. M., Vianey-Saban, C., Petit, F., Hubert-Buron, A., Eberschweiler, P. T., Gajdos, V., & Labrune, P. (2011). Glucose-6-phosphatase deficiency. *Orphanet journal of rare diseases*, 6, 27. <https://doi.org/10.1186/1750-1172-6-27>.
- [12] Chou, J. Y., Jun, H. S., & Mansfield, B. C. (2015). Type I glycogen storage diseases: disorders of the glucose-6-phosphatase/glucose-6-phosphate transporter complexes. *Journal of inherited metabolic disease*, 38 (3), 511–519. <https://doi.org/10.1007/s10545-014-9772-x>.
- [13] Santos, B. L., Souza, C. F., Schuler-Faccini, L., Refosco, L., Epifanio, M., Nalin, T., Vieira, S. M., & Schwartz, I. V. (2014). Glycogen storage disease type I: clinical and laboratory profile. *Jornal de pediatria*, 90 (6), 572–579. <https://doi.org/10.1016/j.jped.2014.02.00>.
- [14] Steunenbergh, T., Peek, F., Hoogeveen, I. J., Mitchell, J. J., Mundy, H., de Boer, F., Lubout, C., de Souza, C. F., Weinstein, D. A., & Derks, T. (2018). Safety issues associated with dietary management in patients with hepatic glycogen storage disease. *Molecular genetics and metabolism*, 125 (1-2), 79–85. <https://doi.org/10.1016/j.ymgme.2018.07.004>.

- [15] Fall, P. J., & Szerlip, H. M. (2005). Lactic acidosis: from sour milk to septic shock. *Journal of intensive care medicine*, 20 (5), 255–271. <https://doi.org/10.1177/0885066605278644>.
- [16] Kraut, J. A., & Kurtz, I. (2001). Use of base in the treatment of severe acidemic states. *American journal of kidney diseases: the official journal of the National Kidney Foundation*, 38 (4), 703–727. <https://doi.org/10.1053/ajkd.2001.27688>.
- [17] Karkar A. (2019). Continuous renal replacement therapy: Principles, modalities, and prescription. *Saudi journal of kidney diseases and transplantation: an official publication of the Saudi Center for Organ Transplantation, Saudi Arabia*, 30 (6), 1201–1209. <https://doi.org/10.4103/1319-2442.275463>.
- [18] Liu, Y., Ouyang, B., Chen, J., Chen, M., Ma, J., Wu, J., Huang, S., Li, L., Liu, Z., & Guan, X. (2014). Effects of different doses in continuous veno-venous hemofiltration on plasma lactate in critically ill patients. *Chinese medical journal*, 127 (10), 1827–1832.
- [19] Song Yan, Li Wei, Zhang Yong, Jing Danqing, Chen Yuxi, Gong Ping. (2002). Comparison of continuous renal replacement therapy and regular hemodialysis in severe lactic acidosis therapy. *Chinese blood purification* (06), DOI: CNKI: Sun: zgjh. 0.2002-06-002.
- [20] Kruse, O., Grunnet, N., & Barfod, C. (2011). Blood lactate as a predictor for in-hospital mortality in patients admitted acutely to hospital: a systematic review. *Scandinavian journal of trauma, resuscitation and emergency medicine*, 19, 74. <https://doi.org/10.1186/1757-7241-19-74>.
- [21] Oster, Y., Wexler, I. D., Heyman, S. N., & Fried, E. (2016). Recoverable, Record-High Lactic Acidosis in a Patient with Glycogen Storage Disease Type 1: A Mixed Type A and Type B Lactate Disorder. *Case reports in medicine*, 2016, 4362743. <https://doi.org/10.1155/2016/4362743>.